

Magnets in the GI tract

The American Society for Gastrointestinal Endoscopy (ASGE) Technology Committee provides reviews of existing, new, or emerging endoscopic technologies that have an impact on the practice of GI endoscopy. Evidence-based methodology is used, with a MEDLINE literature search to identify pertinent preclinical and clinical studies on the topic, and a MAUDE (U.S. Food and Drug Administration Center for Devices and Radiological Health) database search to identify the reported adverse events of a given technology. Both are supplemented by accessing the “related articles” feature of PubMed and by scrutinizing pertinent references cited by the identified studies. Controlled clinical trials are emphasized, but, in many cases, data from randomized controlled trials are lacking. In such cases, large case series, preliminary clinical studies, and expert opinions are used. Technical data are gathered from traditional and Web-based publications, proprietary publications, and informal communications with pertinent vendors. For this review, the MEDLINE database was searched through February 2013 by using the keywords magnet, gastroesophageal, capsule, enteral feeding, colonoscopy, NOTES, endoscopic submucosal dissection, magnetic nanoparticle, reflux, incontinence.

Reports on Emerging Technologies are drafted by 1 or 2 members of the ASGE Technology Committee, reviewed and edited by the committee as a whole, and approved by the governing board of the ASGE. These reports are scientific reviews provided solely for educational and informational purposes. Reports on Emerging Technologies are not rules and should not be construed as establishing a legal standard of care or as encouraging, advocating, requiring, or discouraging any particular treatment or payment for such treatment.

BACKGROUND

Magnets are of interest to the endoscopist or surgeon because they exert a force over a distance and can therefore be used to control instruments remotely or to create compression forces. Applications of magnets or magnetic materials in the GI tract will be reviewed.

EMERGING TECHNOLOGY AND POTENTIAL APPLICATIONS

Magnetic capsule manipulation

Until recently, capsule endoscopes have not been maneuverable. Currently available systems are propelled by spontaneous GI motility, which may result in areas of interest being passed too quickly and large cavities (eg, stomach, colon) being inadequately visualized. Capsules that use external magnetic fields for steering are being evaluated in clinical trials.

There are currently two device systems in late-stage development. The Magnetic Maneuverable Capsule (MMC, NEMO, and Given Imaging, Yoqneam, Israel) is a modification of a standard Given Imaging colon capsule, with magnetic disks inserted inside one dome. The capsule is maneuvered with the help of a handheld external magnet moved across the patient's abdominal surface. The MMC transmits images from one end of the capsule to the data recorder via a set of skin sensors. The images can be viewed in real time or after the examination is complete.¹

The other magnetic capsule system (Siemens Medical, Erlangen, Germany and Olympus America, Center Valley, Pa) consists of a guidance magnet, an image processing and guidance information system (consisting of a console viewed by the operator and a scanner for the patient to lie in), and a capsule endoscope. After swallowing the capsule (11 × 33 mm), the patient is positioned on a bed that resembles a magnetic resonance imaging scanner, with the upper abdomen at the center of an electromagnetically generated field. The magnet system generates varying magnetic fields that are controlled by a “joystick” to navigate the capsule. Cameras at both ends of the capsule transmit images.^{2,3} Neither of these systems are currently commercially available.

The performance of the MMC in the stomach was evaluated in a small study of 10 healthy volunteers with the use of a handheld magnet. The procedure appeared to be safe, well-tolerated, and technically feasible. Maneuverability of the capsule within the gastric lumen was considered excellent by the authors, and visualization of the mucosa was high in the majority of patients. However, visualization of the mucosa was not complete because of fluid blocking the view of the most apical parts of the fundus and suboptimal gastric distention.¹ Another study of 10 healthy volunteers evaluated the performance of the MMC in the esophagus. Magnetic forces were not strong enough to hold the capsule against peristalsis when it approached

the gastroesophageal junction. The dwell time in the esophagus was found to be highly variable, leading to the conclusion that remote control of the MMC in the esophagus of healthy volunteers is feasible, but higher magnetic forces may be needed.⁴

The performance of the Siemens-Olympus system in the stomach was evaluated in a feasibility study of 53 participants (29 healthy volunteers and 24 patients). There was technical failure in 1 individual. In the 52 remaining cases, examiners determined that the antrum, body, fundus, and cardia were fully visualized in 98%, 96%, 73%, and 75% of cases, respectively. The mean duration of the examinations was 30 minutes (range 8-50 minutes). No significant capsule-related adverse events occurred. The authors also report that results improved with practice.²

Magnet-assisted enteral tube placement and electromagnetic tube tracking

Placement of nasogastric feeding tubes past the pylorus is often done blindly at the bedside or under fluoroscopic guidance. Failure to pass the tube beyond the pylorus occurs frequently. Bedside methods that could confirm the correct placement, with the ability to guide the tube directly into the duodenum or monitor the progress of the tube while it is being manipulated, would be helpful.

Two magnet-assisted feeding tubes are commercially available. The Syncro-BlueTub (Syncro Medical Innovations, Macon, Ga) is a feeding tube (8F and 12F) with a stylet that has small magnets at its tip.⁵ The distal end of the tube contains a magnetic field sensor that is connected to an indicator light at the proximal end of the tube. A handheld external steering magnet is used to maneuver the tube through the pyloric sphincter. The indicator light signals when the external magnet has captured the magnet on the distal tip. To verify placement in the duodenum, duodenal fluid is aspirated and applied to pH paper that comes with the kit. The presence of alkaline fluid suggests post-pyloric placement, which should be verified by radiography. The Syncro-BlueTube was evaluated in 288 critically ill patients (329 intubations). Mean procedure time was 15 minutes. In 293 cases (89.1%), the tube was placed beyond the pyloric sphincter. In 139 insertions (42.2%), the tube tip was in the distal portion of the duodenum or the jejunum.⁵

The Cortrak enteral access system (Corpak MedSystems, Buffalo Grove, Ill) consists of a feeding tube with a magnetic stylet. An electromagnetic sensing device is used to track the path of the feeding tube during placement; this device does not allow for external magnetic manipulation of the tube (Fig. 1). The Cortrak 2 enteral access system has U.S. Food and Drug Administration (FDA) clearance for use in confirming tube tip location in lieu of radiography.⁶

The Cortrak enteral feeding system was evaluated in 66 critically ill patients randomly assigned (2:1 ratio) to receive an electromagnetically visualized jejunal feeding tube or an endoscopically placed jejunal tube. The correct

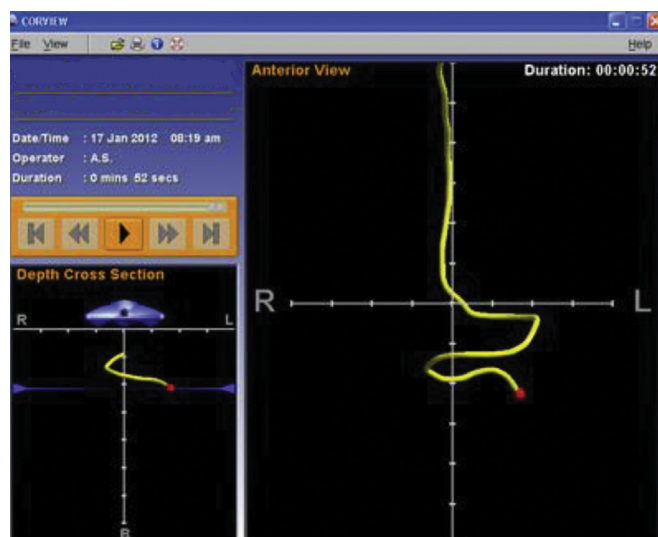


Figure 1. The Cortrak EAS system is based on the same principle as electromagnetic navigation colonoscopy. Changes of a magnetic field generated by a moving magnet are registered by an external antenna and rendered as an image by a viewing application. Image courtesy of CORPAK MedSystems.

jejunal tube position was reached in 21 of 22 patients with the endoscopic technique and in 40 of 44 patients with the electromagnetically visualized jejunal tube (95% vs 91%; $P =$ not significant).⁷

Magnetic endoscopic imaging—magnetic navigation colonoscopy

Loop formation during colonoscopy often can impede colonoscope advancement, especially for trainees. Visualization of loops may be advantageous when a redundant colon is encountered and for teaching colonoscopy.

The ScopeGuide system (Olympus, Center Valley, Pa) uses electromagnetic fields to display colonoscope progress and loop formation. The original system used a through-the-scope probe, which is still commercially available. Newer Olympus colonoscopes have built-in magnetic coils, obviating the need to pass a probe through the colonoscope. Low-strength magnetic fields are generated by a series of tiny wire coils positioned along the length of the colonoscope or probe. The magnetic fields from these wire coils induce an electric current in an external sensor coil. The positional raw data are converted into real-time 3-dimensional views of the colonoscope shaft configuration and its location within the abdomen on a separate computer monitor.

A study of 810 consecutive patients randomized to magnetic endoscopic imaging (MEI) or standard colonoscopy with on-demand fluoroscopy showed that the cecal intubation rate for inexperienced endoscopists was significantly higher in the MEI group (77.8%) compared with that of the standard group (56.0%; $P = .02$) but not for experienced endoscopists (94.0% for MEI and 96.0% for standard group; $P = .87$).⁸

A study of 1000 patients who were randomized to MEI and conventional colonoscopy showed similar results; time to cecal intubation did not differ between the groups. However, the duration of abdominal compression was significantly shorter in MEI-guided colonoscopy, and fewer turn maneuvers were needed per patient.⁹

A recent, randomized, controlled study evaluated the potential benefits of MEI in nonsedated colonoscopy (n = 160). No difference was seen in patient perception of pain or willingness to undergo unsedated examinations when the MEI versus the conventional colonoscope was used.¹⁰

Magnet-assisted stent and foreign body removal

There are numerous options for foreign body removal in the upper digestive tract and rectum. Most involve the use of snares, baskets, forceps, or a combination of these instruments passed through the working channel of an endoscope. Multiple case reports describe how magnets can be used in conjunction with endoscopy to aid in removal of ingested ferromagnetic objects such as batteries.¹¹ Removal of endoscopically placed biliary and pancreatic stents by using an external magnet could obviate the need for a second endoscopy (Fig. 2). A feasibility study of 5 pigs with ferromagnetic biliary stents found that all could be removed with the use of an external magnet.¹² Currently, no systems for foreign body removal are commercially available.

Magnetic anchor–assisted endoscopic submucosal dissection

Gotoda et al have reported their experience of using a magnetic anchor in assisting 25 endoscopic submucosal dissection (ESD) procedures.¹³ ESD is more difficult to perform in certain locations of the stomach than in others where retractors would be helpful. A magnetic anchor is used to overcome the limitation of the standard ESD procedure of “one-hand surgery” by placing it at the edge of the incised mucosa of the lesion. Magnetic traction can be applied to the anchor from any direction by using an extracorporeal electromagnet control system (Fig. 3). With the magnet traction, the incised mucosa can be opened to expose the submucosal layer for further dissection. The authors concluded that magnetic-anchor-guided ESD is a feasible and safe method that enables excellent visualization of the tissue and facilitates gastric ESD in patients with early gastric cancer.¹³

SURGICAL APPLICATIONS

Linx, Fenix, and other devices

In 2012, the FDA approved the Linx Reflux Management System (Torax Medical, Shoreview, Minn) for patients with GERD who are symptomatic despite maximal medical therapy. The Linx system is composed of a series of titanium

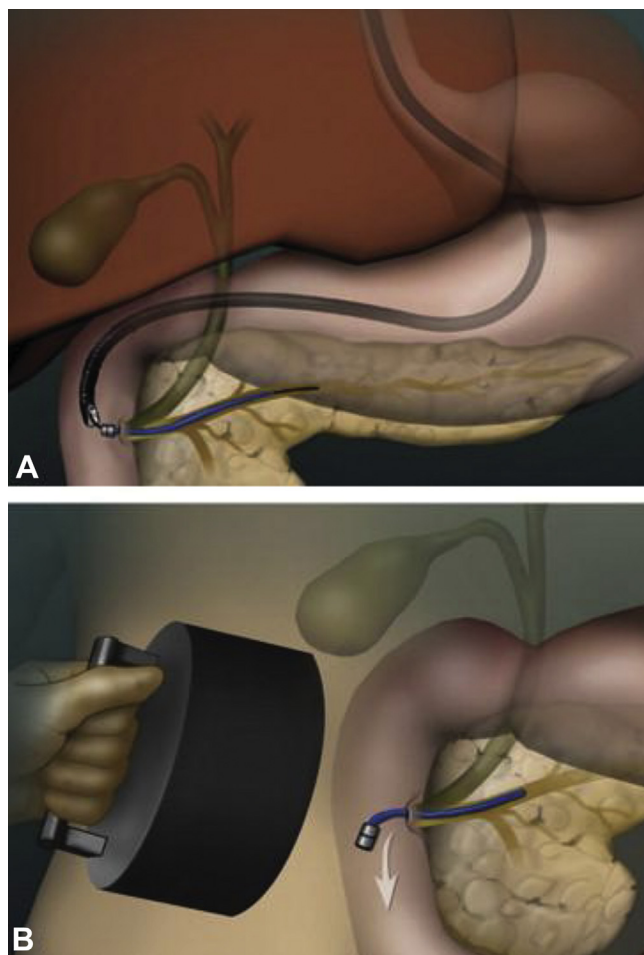


Figure 2. **A**, A strong external permanent magnet attracts a biliary or pancreatic stent equipped with a magnetic proximal end. **B**, By use of appropriate maneuvers, the stent can be dislodged from its initial position to pass naturally. Reprinted with permission from the American Society for Gastrointestinal Endoscopy: Ryou M, Cantillon-Murphy P, Shaikh SN, et al. Magnetic pancreaticobiliary stents and retrieval system: obviating the need for repeat endoscopy (with video). *Gastrointest Endosc* 2012;75:888-92.e1.

beads, each with a magnetic core, connected with independent titanium wires to form a ring shape. The magnetic beads are wrapped around the lower esophageal sphincter by using laparoscopy. A tunnel is created between the posterior esophageal wall and the posterior vagal trunk, where the device is passed through and then wrapped around the esophagus, and the ends are then secured to each other.

A prospective, uncontrolled trial of 100 patients with the Linx device, with 3-year follow-up, was recently published.¹⁴ The primary endpoint was a normalization of esophageal acid exposure or 50% reduction in acid exposure at 1 year; this endpoint was met by 64% of patients. The secondary endpoints were a 50% improvement in GERD-related quality of life or 50% reduction in proton pump inhibitor use; these endpoints were met by 93% and 92% of patients, respectively. The most frequently reported adverse event was dysphagia, occurring in 68% immediately

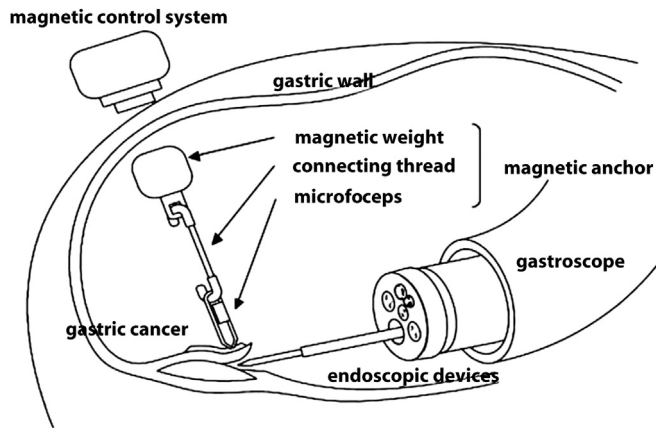


Figure 3. External magnetic forces transmitted through the abdominal wall can be used intra-abdominally in a multitude of ways; for example, to retract tissue during endoscopic submucosal dissection, as shown here, but also to move cameras and other instruments, potentially obviating the need for additional incisions. Reprinted with permission from the American Society for Gastrointestinal Endoscopy: Gotoda T, Oda I, Tamakawa K, et al. Prospective clinical trial of magnetic-anchor-guided endoscopic submucosal dissection for large early gastric cancer (with videos). *Gastrointest Endosc* 2009;69:10-15.

postoperative; this decreased to 11% at 1 year. Bloating and pain also were reported frequently (14% and 25%, respectively). Serious adverse events occurred in 6 patients (dysphagia in 3, nausea/vomiting in 3); 4 patients required removal of the device.

A similar device, the Fenix Continence Restoration System, is intended for the treatment of fecal incontinence and has received CE (*Conformité Européenne*) Mark approval for treatment of fecal incontinence and is currently available for sale only in Europe. It is tunneled around the anal sphincters by use of a single incision.

The initial experience with the Fenix magnetic anal sphincter (MAS) (n = 14) was published in 2010. The study demonstrated significant improvement in fecal incontinence and quality of life. Pain after magnetic anal sphincter device implantation was mild and localized and resolved without surgical intervention. Three patients developed wound infections. Overall, at the end of the study, two patients had the devices explanted and one patient passed the device spontaneously.¹⁵

Minimal access surgery, natural orifice transluminal endoscopic surgery (NOTES), and magnetic compression anastomosis magnets also are being developed to assist in minimal access surgery and NOTES.¹⁶⁻²²

Creation of magnetic compression anastomoses (suture-free anastomoses) exploits the fact that two opposing magnets in the GI tract will cause necrosis of the intervening tissue (Fig. 4). Different types and shapes of magnets have been used to create magnetic anastomoses.²³⁻³³

The “magnamosis” technique uses two symmetrical magnetic rings. One magnetic ring is delivered into each of the two intestinal segments to be anastomosed. When brought

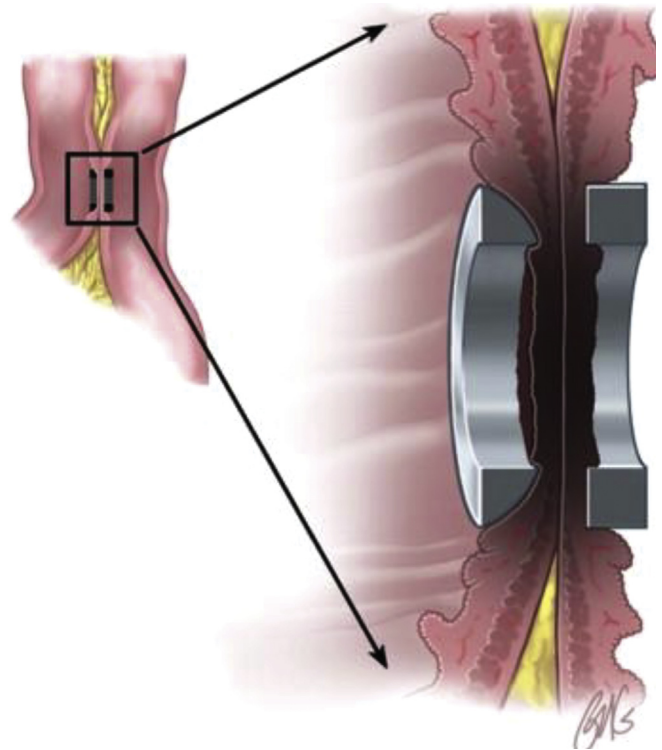


Figure 4. Principle of magnetic compression anastomosis. Two ring magnets opposed to each other will compress the opposing walls of, for example, bowel loops. Pressure necrosis occurs, and within a few weeks an anastomosis will be created. Smaller magnets may pass spontaneously but may not create a large enough lumen. To obtain immediate functionality, the intervening mucosa could be excised (Fig. 5). Reprinted with permission from Elsevier: Jamshidi R, Stephenson JT, Clay JG, et al. Magnamosis: magnetic compression anastomosis with comparison to suture and staple techniques. *J Ped Surg* 2009;44, 222-8.

into magnetic proximity, the magnetic rings self-align and mate, compressing the intervening bowel walls together. The center can be opened for immediate patency. Over 3 to 7 days, the inner edge necroses, and the outer circumference remodels and heals. Complete necrosis of the intervening tissue is avoided by a graded magnetic effect, in which the magnetic attraction at the outer circumference is not as great. The “bowel sandwich” created by the two mated magnetic rings and the intervening necrosed bowel walls falls into the lumen and is expelled, leaving a patent and secure anastomosis.²⁴ The device is not yet commercially available but, according to the developers, a 510(k) application has been filed with the FDA.²⁵

The *smart self-assembling magnets for endoscopy* (SAMSEN) device was evaluated in a proof-of-concept study in a porcine model. The device consists of hinged magnets that, when lined up longitudinally, can be delivered through a catheter. Once outside the catheter, these magnets self-assemble into a predetermined shape. When the magnets occupy the stomach and jejunum, the magnetic shapes approximate to form a gastrojejunostomy after the intervening tissue necroses or is cut (Fig. 5).²⁶ The device

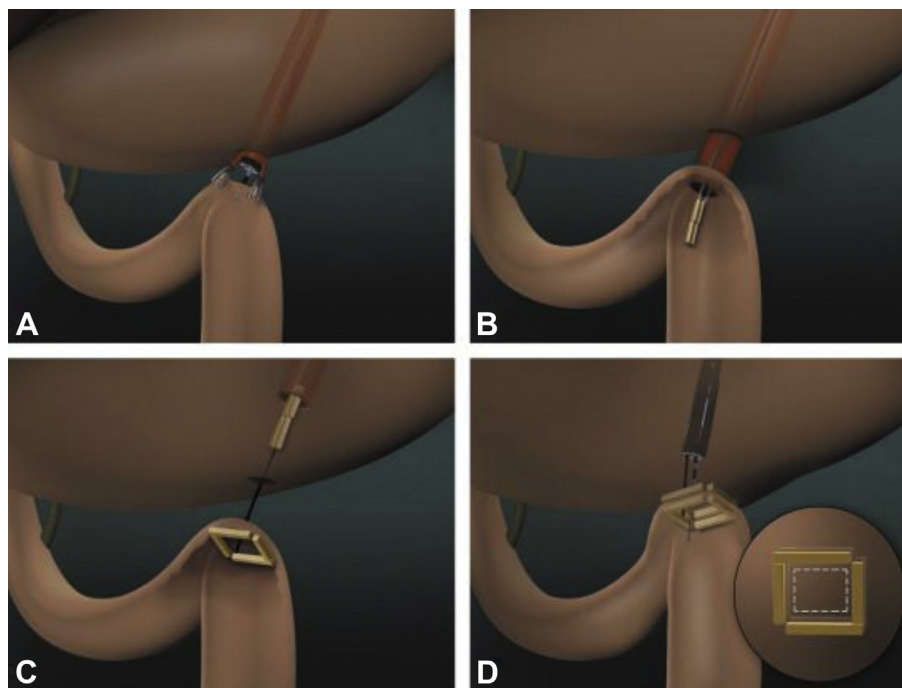


Figure 5. Smart, self-assembling magnets for endoscopy (SAMSSEN) are a potential solution to some of the problems encountered with ring magnets. The following illustrates the steps of their deployment: **A**, Natural orifice transluminal endoscopic surgery gastrotomy is followed by small-bowel mobilization and enterotomy creation by using a custom grasping overtube. **B**, Injection of the small-bowel magnet. **C**, Opening of the small-bowel magnet followed by deployment of the gastric magnet. **D**, Mating of magnets followed by immediate gastrojejunostomy access. Reprinted with permission from the American Society for Gastrointestinal Endoscopy: Ryou M, Cantillon-Murphy P, Azagury D, et al. Smart self-assembling magnets for endoscopy (SAMSSEN) for transoral endoscopic creation of immediate gastrojejunostomy (with video). *Gastrointest Endosc* 2011;73:353-9.

is currently undergoing commercial development by GI Windows, an affiliate of Beacon Endoscopic (Newton, Mass).²⁷

The Cook Magnetic Anastomosis Device (Cook Medical, Bloomington, Ind) consists of two magnetic rings used to create a compression anastomosis. However, after a fistula is created, the magnets are removed, and a special self-expandable covered metal stent with wide flanges is deployed to maintain patency. This device has been investigated in a multicenter clinical trial for the palliation of malignant gastric outlet obstruction. A success rate of 66.7% (12/18 patients) was achieved; one serious adverse event (stent perforation) occurred leading to the death of the patient and early termination of the study. Three patients (25%) experienced an adverse device effect (stent migration).²⁸ This device is not commercially available.

Magnetic compression anastomoses have been used clinically in the nonsurgical treatment of esophageal atresia,²⁹ in the treatment of biliary strictures after liver transplantation,³⁰ to create biliary-enteric anastomoses to bypass malignant obstruction,³² and to create a cyst-gastrostomy.³³

Other applications

Magnetic nanoparticles are a class of nanoparticles (ie, engineered particulate materials of <100 nm) that can be manipulated under the influence of an external magnetic

field.³⁴ The application of nanotechnology in GI endoscopy is still in its infancy, but interest in related devices and techniques is emerging.³⁵ Biological applications of magnetic nanoparticles recently have been reviewed comprehensively.^{36,37} Endoscopists and endosonographers may be involved in deploying magnetic nanoparticles in specific target locations. Magnetic nanoparticles could be used as a drug delivery system, especially for cytotoxic drugs, and as heat mediators for hyperthermia for localized tumor therapy and for a number of other applications.³⁸⁻⁴⁵

Research agenda

Clinical research of magnetic capsule manipulation is currently in early stages, and further work is necessary. Hybrid systems with capsules that can propel themselves independently but are steered from the outside may need to be developed. The potential benefits of MEI in the setting of difficult colonoscopies or in the training of gastroenterology fellows need to be further defined. Prospective studies are necessary to evaluate whether magnet-assisted methods of feeding tube placement are associated with efficacy, safety, and cost benefits. Whether external magnets can be used to remove magnetized pancreas and/or biliary stents in humans has not been evaluated. Long-term data about the safety and efficacy of the

Linx device are needed. The Linx band is currently being deployed laparoscopically; however, a NOTES approach could be explored. Compression anastomosis that uses magnets has potential applications in a wide variety of settings, but further work is required before these devices and methods can become mainstream. Delivery methods, especially in narrow lumens, need to be optimized.

Summary

There are many different applications of magnetic technology in the GI tract. Some are in early stages of development, whereas others have attained or are in the process of attaining FDA approval or clearance. This is a vibrant field with many opportunities for device development and clinical research.

Abbreviations: ESD, endoscopic submucosal dissection; FDA, Food and Drug Administration; MEI, magnetic endoscopic imaging; MMC, Magnetic Maneuverable Capsule; NOTES, natural orifice transluminal endoscopic surgery.

REFERENCES

- Keller J, Fibbe C, Volke F, et al. Inspection of the human stomach using remote-controlled capsule endoscopy: a feasibility study in healthy volunteers (with videos). *Gastrointest Endosc* 2011;73:22-8.
- Rey J, Ogata H, Hosoe N, et al. Der Einsatz einer steuerbaren Endoskopiekapsel zur Untersuchung des Magens [German]. *Endoskopie heute* 2010;23:285-9.
- Siemens and Olympus Healthcare. Magnetically guided capsule endoscope system for comfortable examination of the stomach—More than 50 participants in the first successful study. Available at: <http://www.siemens.com/press/en/materials/healthcare/2010-10-Kapselendoskopie.php>. Accessed January 26, 2013.
- Keller J, Fibbe C, Volke F, et al. Remote magnetic control of a wireless capsule endoscope in the esophagus is safe and feasible: results of a randomized, clinical trial in healthy volunteers. *Gastrointest Endosc* 2010;72:941-6.
- Gabriel SA, Ackermann RJ. Placement of nasoenteral feeding tubes using external magnetic guidance. *JPEN J Parenter Enteral Nutr* 2004;28:119-22.
- CORPAK MedSystems UK—CORTRAK. Available at: <http://www.corpakmedsystemsuk.com/Cortrak/cortrakUK.html>. Accessed January 25, 2013.
- Holzinger U, Brunner R, Miehsler W, et al. Jejunal tube placement in critically ill patients: a prospective, randomized trial comparing the endoscopic technique with the electromagnetically visualized method. *Crit Care Med* 2011;39:73-7.
- Holme Ö, Höie O, Matre J, et al. Magnetic endoscopic imaging versus standard colonoscopy in a routine colonoscopy setting: a randomized, controlled trial. *Gastrointest Endosc* 2011;73:1215-22.
- Dechéne A, Jochum C, Bechmann LP, et al. Magnetic endoscopic imaging saves abdominal compression and patient pain in routine colonoscopies. *J Dig Dis* 2011;12:364-70.
- Shergill AK, McQuaid KR, DeLeon A, et al. Randomized trial of standard versus magnetic endoscope imaging colonoscopes for unsedated colonoscopy. *Gastrointest Endosc* 2012;75:1031-6.e1.
- Coash M, Wu GY. Endoscopic removal of a long sharp metallic foreign body by a snared magnet: an attractive solution. *J Dig Dis* 2012;13:239-41.
- Ryou M, Cantillon-Murphy P, Shaikh SN, et al. Magnetic pancreaticobiliary stents and retrieval system: obviating the need for repeat endoscopy (with video). *Gastrointest Endosc* 2012;75:888-92.e1.
- Gotoda T, Oda I, Tamakawa K, et al. Prospective clinical trial of magnetic-anchor-guided endoscopic submucosal dissection for large early gastric cancer (with videos). *Gastrointest Endosc* 2009;69:10-5.
- Ganz RA, Peters JH, Horgan S, et al. Esophageal sphincter device for gastroesophageal reflux disease. *New Engl J Med* 2013;368:719-27.
- Mantoo S, Meurette G, Podevin J, et al. The magnetic anal sphincter: a new device in the management of severe fecal incontinence. *Ex Rev Med Dev* 2012;9:483-90.
- Lehman AC, Berg KA, Dumpert J, et al. Surgery with cooperative robots. *Comput Aided Surg* 2008;13:95-105.
- Lehman AC, Dumpert J, Wood NA, et al. Natural orifice cholecystectomy using a miniature robot. *Surg Endosc* 2009;23:260-6.
- Padilla BE, Dominguez G, Millan C, et al. Initial experience with magnet-assisted single trocar appendectomy in children. *J Laparoendoscop Adv Surg Tech* 2012;120627085549005.
- Best SL, Bergs R, Gedeon M, et al. Maximizing coupling strength of magnetically anchored surgical instruments: How thick can we go? *Surg Endosc* 2011;25:153-9.
- ImanLap—Magnetic devices for less surgery. Available at: <http://imanlap.com/>. Accessed February 2, 2013.
- Martinez-Ferro M. International innovations in pediatric minimally invasive surgery: the Argentine experience. *J Ped Surg* 2012;47:825-35.
- Uematsu D, Akiyama G, Magishi A, et al. Single-access laparoscopic left and right hemicolectomy combined with extracorporeal magnetic retraction. *Dis Colon Rectum* 2010;53:944-8.
- Myers C, Yellen B, Evans J, et al. Using external magnet guidance and endoscopically placed magnets to create suture-free gastro-entestinal anastomoses. *Surg Endosc* 2010;24:1104-9.
- Gonzales KD, Douglas G, Pichakron KO, et al. Magnamosis III: delivery of a magnetic compression anastomosis device using minimally invasive endoscopic techniques. *J Ped Surg* 2012;47:1291-5.
- Magnamosis Pediatric Device Consortium. Available at: <http://www.pediatricdeviceconsortium.org/devices/magnamosis>. Accessed February 3, 2013.
- Ryou M, Cantillon-Murphy P, Azagury D, et al. Smart self-assembling magnets for endoscopy (SAMSEN) for transoral endoscopic creation of immediate gastrojejunostomy (with video). *Gastrointest Endosc* 2011;73:353-9.
- Newsroom: Beacon Endoscopic. Available at: <http://www.beaconendoscopic.com/newsroom>. Accessed February 3, 2013.
- Van Hooft JE, Vleggaar FP, Le Moine O, et al. Endoscopic magnetic gastroenteric anastomosis for palliation of malignant gastric outlet obstruction: a prospective multicenter study. *Gastrointest Endosc* 2010;72:530-5.
- Zaritzky M, Ben R, Zylberg GI, et al. Magnetic compression anastomosis as a nonsurgical treatment for esophageal atresia. *Pediatr Radiol* 2009;39:945-9.
- Jang SI, Kim J-H, Won JY, et al. Magnetic compression anastomosis is useful in biliary anastomotic strictures after living donor liver transplantation. *Gastrointest Endosc* 2011;74:1040-8.
- Jamidar P, Cadeddu M, Mosse A, et al. A hinged metalloplastic anastomotic device: a novel method for choledochoduodenostomy. *Gastrointest Endosc* 2009;69:1333-8.
- Avaliani M, Chigogidze N, Nepochai A, et al. Magnetic compression biliary-enteric anastomosis for palliation of obstructive jaundice: initial clinical results. *J Vasc Intervention Radiol* 2009;20:614-23.
- Tajima Y, Yamanouchi E, Fukuda K, et al. A secure and less-invasive new method for creation of an internal enteric fistula by using magnets as a therapeutic modality for pancreaticocutaneous fistula: a case report. *Gastrointest Endosc* 2004;60:463-7.
- Shubayev VI, Pisanic TR, Jin S. Magnetic nanoparticles for theragnostics. *Adv Drug Deliv Rev* 2009;61:467-77.
- Jha A, Goenka M, Nijhawan S, et al. Nanotechnology in gastrointestinal endoscopy: a primer. *J Dig Endosc* 2012;3:77-80.

36. Colombo M, Carregal-Romero S, Casula MF, et al. Biological applications of magnetic nanoparticles. *Chem Soc Rev* 2012;41:4306-34.
37. Reddy LH, Arias JL, Nicolas J, et al. Magnetic nanoparticles: design and characterization, toxicity and biocompatibility, pharmaceutical and biomedical applications. *Chem Rev* 2012;112:5818-78.
38. Wang Z, Wang L, Brown SI, et al. Ferromagnetization of target tissues by interstitial injection of ferrofluid: formulation and evidence of efficacy for magnetic retraction. *IEEE Transact Biomed Engineer* 2009;56:2244-52.
39. Wang Z, Brown AW, Brown SI, et al. Intra-luminal injection of ferro-fluid for magnetic bowel retraction in minimal access surgery. In: 2010 IEEE/ASME International Conference on Mechatronics and Embedded Systems and Applications (MESA) 2010:168-73.
40. Khandhar AP, Ferguson RM, Simon JA, et al. Tailored magnetic nanoparticles for optimizing magnetic fluid hyperthermia. *J Biomed Materials Res Part A* 2012;100A:728-37.
41. Yigit MV, Moore A, Medarova Z. Magnetic nanoparticles for cancer diagnosis and therapy. *Pharmaceut Res* 2012;29:1180-8.
42. Jordan A, Scholz R, Maier-Hauff K, et al. Presentation of a new magnetic field therapy system for the treatment of human solid tumors with magnetic fluid hyperthermia. *J Magnetism Magnetic Mat* 2001;225:118-26.
43. Maier-Hauff K, Rothe R, Scholz R, et al. Intracranial thermotherapy using magnetic nanoparticles combined with external beam radiotherapy: results of a feasibility study on patients with glioblastoma multiforme. *J Neurooncol* 2007;81:53-60.
44. Wust P, Gneveckow U, Johannsen M, et al. Magnetic nanoparticles for interstitial thermotherapy—feasibility, tolerance and achieved temperatures. *Int J Hyperthermia* 2006;22:673-85.
45. MagForce AG—Physicians' Information. Available at: <http://www.magforce.de/en/studien/aerzte-informationen/article/magforce-unterzeichnet-vertriebsvereinbarung-mit-tuerkischer-vertriebsgesellschaft-fuer-medinizinprodu.html>. Accessed January 21, 2013.

Prepared by:

ASGE TECHNOLOGY COMMITTEE

Klaus T. Gottlieb, MD, MBA

Subhas Banerjee, MD

Bradley A. Barth, MD, NASPGHAN Representative

Yasser M. Bhat, MD

Shailendra S. Chauhan, MD

Vani Konda, MD

John T. Maple, DO

Faris Murad, MD

Patrick Pfau, MD

Douglas Pleskow, MD

Uzma D. Siddiqui, MD

Jeffrey L. Tokar, MD

Amy Wang, MD

Sarah A. Rodriguez, MD, Committee Chair

This document is a product of the ASGE Technology Assessment Committee. This document was reviewed and approved by the governing board of the American Society for Gastrointestinal Endoscopy.
