

Enteral stents

The American Society for Gastrointestinal Endoscopy (ASGE) Technology Committee provides reviews of existing, new, or emerging endoscopic technologies that have an impact on the practice of GI endoscopy. Evidence-based methodology is used, with a MEDLINE literature search to identify pertinent clinical studies on the topic and a MAUDE (U.S. Food and Drug Administration Center for Devices and Radiological Health) database search to identify the reported complications of a given technology. Both are supplemented by accessing the “related articles” feature of PubMed and by scrutinizing pertinent references cited by the identified studies. Controlled clinical trials are emphasized, but in many cases, data from randomized, controlled trials are lacking. In such cases, large case series, preliminary clinical studies, and expert opinions are used. Technical data are gathered from traditional and Web-based publications, proprietary publications, and informal communications with pertinent vendors.

Technology Status Evaluation Reports are drafted by 1 or 2 members of the ASGE Technology Committee, reviewed and edited by the committee as a whole, and approved by the Governing Board of the ASGE. When financial guidance is indicated, the most recent coding data and list prices at the time of publication are provided. For this review, the MEDLINE database was searched through August 2010 for articles related to enteral, esophageal, duodenal, and colonic stents.

Technology Status Evaluation Reports are scientific reviews provided solely for educational and informational purposes. Technology Status Evaluation Reports are not rules and should not be construed as establishing a legal standard of care or as encouraging, advocating, requiring, or discouraging any particular treatment or payment for such treatment.

BACKGROUND

Stents are devices used to maintain or restore the lumen of hollow organs, vessels, and ducts. Current stents available for application in the alimentary tract include self-expandable metal stents (SEMSs) for esophageal, gastroduodenal, and colonic malignant obstruction

and self-expandable plastic stents (SEPSs) for benign or malignant esophageal strictures. This report provides an update on the technical specifications, efficacy, safety, and financial considerations regarding stents for use in the esophagus, stomach, small bowel, and colon.

TECHNICAL CONSIDERATIONS

SEMSs consist of woven, knitted, or laser-cut metal mesh cylinders that exert self-expansive forces until they reach their maximum fixed diameter. They are generally packaged in a compressed form and constrained on a delivery device. SEMSs are composed of stainless steel, alloys such as elgiloy and nitinol, or a combination of nitinol and silicone. Elgiloy, an alloy composed primarily of cobalt, nickel, and chromium, is corrosion resistant and capable of generating high radial forces. Nitinol, an alloy of nickel and titanium, yields increased flexibility that is helpful for stenting sharply angulated regions at the cost of lesser radial force relative to stents made with other metals. All SEMSs come in a variety of lengths and diameters. Most have a proximal and/or distal flare to prevent migration. The various stents that are commercially available in the United States and their unique specifications and features are outlined in [Table 1](#).

To prevent tumor ingrowth, the interstices between the metal mesh of esophageal SEMSs may be wholly or partially covered by a plastic membrane or silicone. Currently available enteral and colonic stents are uncovered. Other stent modifications include looped ends to reduce the risk of mucosal injury and a proximal flared end to minimize the risk of stent migration. One specialized covered SEMS that is intended for tumors located near the gastroesophageal junction (Esophageal Z-stent with Dua Anti-reflux valve; Wilson-Cook Medical, Winston-Salem, NC) uses an extended polyurethane membrane 8 cm beyond the metal portion of the stent to prevent gastroesophageal reflux.

An SEPS (Polyflex; Boston Scientific, Natick, Mass) has been developed for esophageal strictures. This stent has a woven polyester skeleton and is completely covered with a silicone membrane. The silicone prevents tissue ingrowth through the mesh, and the polyester braids on the external surface anchor the stent to the mucosa to limit migration. Radiopaque markers positioned at the middle and ends of the stent facilitate visualization of this nonmetallic device during fluoroscopy. The SEPS comes in a variety of lengths and diameters ([Table 1](#)).

TABLE 1. Specifications and features of stents commercially available in the United States

	Composition	Delivery system diameter/length	Unconstrained outer diameter	Unconstrained lengths (covered length)	List price, \$	Features
Esophageal stents						
Boston Scientific						
Ultraflex NG Covered	Nitinol	5 mm/87-95 cm	18 mm, 23 mm (proximal flare, 23 mm and 28 mm, respectively)	10 cm (7 cm) 12 cm (9 cm) 15 cm (12 cm)	2175	Available in distal or proximal release, suture removal release mechanism, 48%-54% foreshortening with deployment; indicated for resectable and nonresectable malignancies
Ultraflex NG Uncovered	Nitinol	5 mm/87-95 cm	18 mm (23-mm proximal flare)	7 cm 10 cm 15 cm	2025	Available in distal or proximal release, 48%-54% foreshortening with deployment; indicated for resectable and nonresectable malignancies
Polyflex	Polyester/silicone	12-14 mm/70 cm	16 mm (20- mm proximal flare) 18 mm (23-mm proximal flare) 21 mm (25-mm proximal flare)	9 cm 12 cm 15 cm	2395	Indicated for refractory benign strictures, resectable and nonresectable malignancies. Studies have demonstrated safe removal weeks after placement, manual loading onto delivery system required, has radiopaque markers at ends and center, 36%-41% foreshortening with deployment
WallFlex partially Covered	Nitinol/silicone	6.2 mm/78 cm	18 mm (23-mm proximal and distal flare) 23 mm (28-mm proximal and distal flare)	10 cm (7 cm) 12 cm (9 cm) 15 cm (12 cm)	2550	Low-profile 18.5F coaxial delivery system, proximal and distal flares, proximal removal suture, endoscopic transition zone for deployment under direct visualization; indicated for resectable and nonresectable malignancies and concurrent esophageal fistulae
WallFlex fully covered	Nitinol/silicone	6.2 mm/78 cm	18 mm (25-mm proximal flare, 23-mm distal flare) 23 mm (28-mm proximal and distal flare)	10 cm 12 cm 15 cm	2650	Low-profile 18.5F coaxial delivery system with reconstrainability up to 75%, proximal and distal flares, proximal removal suture, endoscopic transition zone for deployment under direct visualization; indicated for resectable and nonresectable malignancies and concurrent esophageal fistulae
Cook Medical						
Evolution partially covered	Nitinol	8 mm/78 cm	20-mm body; 2-mm proximal and distal flanges	8 cm (5 cm) 10 cm (7 cm) 12.5 cm (9.5 cm) 15 cm (12 cm)	1924	Silicone coating on the exterior and interior stent surface, proximal and distal uncovered flanges, lasso loop for repositioning immediately after placement, controlled-release trigger deployment and recapturability, 30-40% foreshortening
Evolution fully covered	Nitinol	8 mm/78 cm	18-mm body, 23-mm proximal and distal flanges 20-mm body, 25-mm proximal and distal flanges	8 cm 10 cm 12 cm	1924	Silicone coating on the exterior and interior stent surface, lasso loops on both ends for repositioning immediately after placement, controlled-release trigger deployment and recapturability, 28-33% foreshortening
Z-Stent with dual antireflux valve	Stainless steel	10.3 mm/70 cm	18-mm body, 25-mm flared end	8 cm 10 cm 12 cm 14 cm	1973 2085 2193 2301	Windsock design reduces possibility of gastroesophageal reflux for stents placed at gastroesophageal junction, no foreshortening, required manual loading of stent into delivery system

TABLE 1. (continued)

	Composition	Delivery system diameter/length	Unconstrained outer diameter	Unconstrained lengths (covered length)	List price, \$	Features
EndoChoice						
Bonastent	Nitinol	6 mm	18-mm body, 24-mm flare	6 cm 8 cm 10 cm 12 cm 14 cm 16 cm	1985	Hooked crosswire geography offers greater conformability
Merit Endotek						
ALIMAXX-ES	Nitinol (laser cut)	7.4 mm/62-67 cm	12-mm mid-body (17-mm proximal flare, 15-mm distal flare) 14-mm mid-body (19-mm proximal flare, 17-mm distal flare) 16-mm mid-body (21-mm proximal flare, 19-mm distal flare) 18-mm mid-body (23-mm proximal flare, 21-mm distal flare) 22-mm mid-body (27-mm proximal flare, 25-mm distal flare)	7 cm 10 cm 120 cm	1900	Laser cut nitinol design results in virtually no stent foreshortening or elongation. Stent contains antimigration struts that reduce stent migration. Polyurethane cover helps to decrease tissue ingrowth. Silicone lining provides a smooth inner lumen. Accurate 1-handed delivery over target site. Soft distal and proximal flares allow patient comfort because of controlled circumferential stent expansion. Indicated for maintaining esophageal luminal patency in esophageal strictures caused by intrinsic and/or extrinsic malignant tumors and for occlusion of esophageal fistulae.
Colonic/enteral stents						
Boston Scientific						
Ultraflex Precision Colonic Stent System	Nitinol	22F/100 cm	25-mm body, 30-mm flare	57 mm 87 mm 117 mm	2125	Over-the-wire proximal suture release for left-sided colonic obstruction; indicated for palliation and as a bridge to surgery for malignant colonic neoplasms
WALLSTENT colonic and duodenal	Elgiloy	3.3 mm/135 cm and 230 cm	20 mm 22 mm	60 mm 90 mm	2225	Through-the-scope deployment possible; reconstrainable before full deployment; Indicated for palliation and as a bridge to surgery for malignant colonic neoplasms
WallFlex colonic	Nitinol	10F/135 cm and 230 cm	22-mm body, 27-mm flared end and 25-mm body, 30-mm flared end	60 mm 90 mm 120 mm	2625	Low-profile 10F through-the-scope/over-the-wire delivery catheter; reconstrainable up to 70% deployment; indicated for palliation and as a bridge to surgery for malignant colonic neoplasms
WallFlex duodenal	Nitinol	10F/230 cm	22-mm body, 27-mm flared end	60 mm 90 mm 120 mm	2625	Low-profile 10F through-the-scope/over-the-wire delivery catheter, reconstrainable up to 70% deployment
Cook Medical						
Colonic Z-Stent	Stainless steel	10.3 mm 40 cm	25-mm body	40 mm 60 mm 80 mm 120 mm	1324 1450 1608 1891	No foreshortening, 35-mm flared end, required manual loading of stent into delivery system

TECHNIQUE

The stricture to be stented is first identified endoscopically. The proximal and distal aspects of the stricture are identified either endoscopically or, in the case of nontraversable strictures, with fluoroscopic guidance. A guidewire is advanced through the stricture, and the stent is positioned across the stricture and then deployed under fluoroscopic and/or endoscopic guidance by release of the constraining mechanism. There are 2 methods of stent delivery: through the scope and over the wire. All enteral SEMS are inserted and deployed over a guidewire. As the stent expands, radial forces anchor it at the site of obstruction. The main differences between delivery systems are the design of the handles, the means of removing the constraining mechanism, and the diameter, which determines the means of deployment. Although the majority of deployment systems release the stent initially at the distal end of the catheter, the Ultraflex Esophageal NG stent (Boston Scientific) is available in both a proximal and distal release system. In contrast to most SEMSs, which are sold in a constrained fashion, the SEPS requires mounting onto the delivery catheter just before use. Also, the colonic Z stent (Cook Medical) requires manual loading of the stent into the delivery system.

One important aspect of deployment is the variable degree of foreshortening that occurs with a majority of SEMSs and SEPSs during the transition from the compressed to fully expanded state. The endoscopist must anticipate and allow for this foreshortening to ensure appropriate placement. Table 1 indicates the foreshortening for each device. The labeled stent length always indicates the length at full expansion.

Dilation to 36F (12 mm) or more is sometimes required to enable passage of the esophageal SEMS, depending on stent type and the character and location of the stricture. In contrast, predeployment dilation is generally not required during gastroduodenal stenting and should be avoided during colonic SEMS placement. Technical details of stent placement and general reviews have been previously published.^{1,2}

Although covered SEMSs can often be repositioned or removed, noncovered SEMSs cannot be easily repositioned or removed once fully deployed. The available SEPS has been designed and demonstrated to be removable, although the manufacturer warns that the safety of removal after 9 months has not been demonstrated.

EFFICACY/COMPARATIVE ANALYSIS

Esophageal stents

Esophageal SEMSs are indicated for palliation of malignant strictures and tracheoesophageal fistulae. SEMSs have largely replaced the use of rigid plastic stents in the esophagus as a result of the lower complication rate with their use.³⁻⁶ SEMSs improve dysphagia in more than 90% of

patients with esophageal cancer.^{4,6} SEMSs also improve dysphagia caused by extrinsic malignant compression; however, outcomes are less optimal in this setting.⁷ In a randomized study, SEMSs were associated with more rapid restoration of oral intake and lower hospital mortality compared with palliative bypass surgery.⁸ A Dutch cooperative study comparing SEMSs with brachytherapy found that SEMSs more rapidly improved dysphagia, but brachytherapy yielded better long-term control of dysphagia and better overall quality of life with fewer complications.⁹ A randomized trial suggested that SEMSs were more effective than laser therapy and required fewer reinterventions.¹⁰ In trials comparing various available SEMSs, no single device was consistently associated with improved outcomes or fewer complications.¹¹⁻¹⁵

Covered SEMSs help prevent tumor ingrowth. In 1 randomized, controlled study, during 6 months of observation, covered stents decreased the necessity of reintervention for tumor ingrowth from 27% to 0%.¹⁶ One specialized partially covered SEMS that is intended for tumors located near the gastroesophageal junction (Esophageal Z-stent with Dua Anti-reflux valve; Cook Medical) uses an extended polyurethane membrane 8 cm beyond the metal portion of the stent to prevent gastroesophageal reflux. In vitro studies, animal data, and clinical series suggest that this stent successfully prevents significant reflux,^{17,18} when stent placement across the esophagogastric junction is required. Randomized trials of similarly designed wind-sock antireflux stents have demonstrated mixed results in the prevention of esophageal acid reflux as determined by reflux scores and 24-hour pH monitoring.¹⁹⁻²¹ Covered SEMSs are effective for palliation of malignant tracheoesophageal fistulae with successful closure of the fistula in 66% to 100% of patients.²²⁻²⁶ When fistulae persist despite esophageal stent placement, bronchoscopic placement of a parallel tracheal stent can facilitate closure.²⁶

The currently available silicone-covered SEPS is approved for treatment of malignant and benign esophageal strictures. Preliminary reports indicate efficacy for malignant strictures similar to that of SEMSs.^{27,28} Although not approved as a removable stent, the complete silicone coating facilitates removal even after it is in place for several months. There are several reports of its use for benign strictures; however, they are uncontrolled and include only small numbers of heterogeneous patients.^{29,30} In 1 series, temporary SEPS placement for anastomotic leaks after esophagectomy resulted in more rapid oral intake, shorter average hospital stay, and improved mortality compared with surgery or conservative therapy.³¹

Covered esophageal stents may be temporarily placed to relieve dysphagia, whereas patients undergo neoadjuvant therapy, thereby acting as a bridge to surgery.³²⁻³⁵ Both plastic³²⁻³⁴ and metal stents³⁵ have been used for this indication, which is yet to be approved by the U.S. Food and Drug Administration. After successful stent placement, improvement in dysphagia scores and nutritional status

was reported in almost all patients. Stent migration is a concern, particularly after initiation of neoadjuvant therapy, and has been reported in 24% to 46% of patients.³²⁻³⁵ Elective removal of the stent has been attempted to reduce the migration risk.³⁶

Gastroduodenal stents

Many studies have reported effective palliation of malignant gastric outlet obstruction in the antrum, proximal small bowel, and gastroenteric anastomoses by endoscopic SEMs placement.³⁷⁻⁴⁶ Only the Wallstent Enteral and the recently introduced Wallflex Duodenal (Boston Scientific) are approved for treatment of malignant gastroduodenal obstruction. However, some series include cases in which esophageal stents with introducer systems long enough to reach the duodenum were used. Technical success rates for both stents are generally greater than 90%, and 60% to 85% of patients are able to eat at least soft mechanical diets. A comprehensive review of 32 case series including 606 patients unable to take oral intake reported successful stent deployment in 97% of patients, and oral intake was possible in all successful cases, with 87% of patients capable of eating at least a mechanical soft diet.⁴⁴

There are limited reports comparing stenting of the gastric outlet or small intestine with surgical bypass. A small randomized, prospective study of 18 patients comparing SEMs placement with surgical bypass found no difference in survival, complication rates, or gastric emptying at 3 months, but the SEMs group had more rapid restoration of oral intake and a shorter mean hospitalization.⁴⁵ Similarly, a retrospective comparison of a cohort of 27 patients with pancreatic cancer causing duodenal obstruction treated with endoscopic stenting or surgical bypass found no difference in survival but a median hospital stay of 4 days in the stent group compared with 14 days in the surgical group.³⁹ A prospective, nonrandomized study of 36 patients found no difference in overall survival or ability to tolerate food 1 month after stent placement or surgical bypass.⁴⁶ Stent placement is usually associated with better short-term outcomes such as the ability to tolerate oral intake, whereas surgery is associated with better long-term outcomes such as lower rates of recurrent obstruction.⁴⁷

Colonic stents

Currently available colonic stents are uncovered, but many investigators have reported using both uncovered and covered esophageal stents in the colon, and the latter may lower the rate of tissue ingrowth and aid in fistula closure.^{48,49} Use of covered stents in the colon may result in higher migration rates.^{50,51} Clinical success rates, defined as relief of obstructive symptoms, are reported in 85% to 90% of patients. Stenting lesions in the right colon was difficult with the previously available over-the-wire colonic stents. However, by using newer through-the-

scope colonic stents, recent studies report rates of technical and clinical successes that are greater than 85%.^{52,53} When SEMs have been used for temporary preoperative decompression (bridge to surgery), success rates for completion of a single-stage elective operation are 60% to 85%.^{1,49,54-62}

A meta-analysis of 10 studies that compared outcomes between colonic stenting and surgery reported that stent insertion was technically successful in 92.6% of 244 patients.⁶³ The length of hospital stay was shorter by 7.7 days in the stent group, which also had lower rates of mortality and medical complications than the surgery group. Although the need for ostomy creation was significantly lower in the stent group, there was no difference in survival between patients who underwent stenting followed by subsequent surgery and those who underwent emergent surgery alone. Similar findings were reported in another single-center retrospective study of 123 patients who underwent surgery or SEMs placement.⁶⁴ Although there was no difference in survival between groups, patients who underwent SEMs placement had a shorter length of hospital stay, fewer acute complications, and lower mortality. A decision model of colonic stent placement versus emergency surgery for obstructive left-sided colon cancer estimated that preoperative colonic SEMs placement would decrease surgical procedures by 23% and reduce the need for a stoma from 43% to 7%.⁶⁵ In a recently concluded randomized trial of 48 patients with obstructive left-sided colon cancer, 67% of patients who underwent endolaparoscopic surgery (colonic stenting followed by elective laparoscopic resection) had successful 1-stage operations compared with only 38% of patients who underwent emergent open surgery.⁶⁶ Taken together, these studies show that colonic stenting for malignant obstruction is associated with less morbidity and cost but no difference in overall survival. Assessment of quality of life (QOL) in patients with terminal colon cancer is challenging. One study reported that SEMs placement in patients with obstructive colon cancer was associated with improved overall QOL and also QOL related specifically to GI symptoms.⁶⁷

There are very limited data on the use of esophageal SEPSs for the management of colonic strictures.⁶⁸ In a report of 3 patients with benign postoperative strictures at the rectosigmoid junction or the sigmoid colon, the placement of esophageal SEPS yielded resolution of strictures and/or symptoms in all patients. In another report of 21 patients with benign colonic strictures, SEMs placement yielded clinical success in 76% with a complication rate of 42%, a majority of which occurred in patients with diverticular strictures.⁶⁹

SAFETY

In addition to the standard risks of endoscopy, SEMs placement in the esophagus is associated with several

severe, life-threatening complications including perforation, hemorrhage, and airway compression.^{2,3,70} Perforation and hemorrhage may be immediate or delayed. Airway compression is an immediate complication, and some have advocated bronchoscopy and possible tracheal stent placement simultaneously or before esophageal stent placement for bulky lesions in the upper esophagus involving or compressing the airways.^{25,71,72} It has been suggested that smaller diameter stents should be chosen for upper esophageal tumors to avoid excessive compressive forces, which can lead to unpleasant symptoms and potentially cause airway compression or pressure necrosis with fistula formation.^{35,73} One case series suggests stents can be successfully placed for tumors within 1 cm of the upper esophageal sphincter, but the authors recommended avoiding large-caliber stents in this region.¹⁵ The overall death rate from palliative stenting of the esophagus has been estimated at 0.5% to 3.3% based on retrospective surveys and reports including both SEMSs and rigid plastic stents.^{3,74,75} Previous radiation or chemotherapy may be associated with an increased rate of complications. Although some series reported an increased incidence of stent-induced complications^{60,76} and mortality,⁷⁷ others revealed no increase in mortality or life-threatening complications with esophageal stent placement in this setting.^{78,79} Other complications of esophageal stent placement include stent occlusion caused by tissue hyperplasia or tumor ingrowth (11%), stent migration (7%), chest pain (12%), gastroesophageal reflux and aspiration pneumonia (8%), and delayed tracheoesophageal fistula caused by pressure necrosis (2%).⁸⁰ The development of ulceration and mucosal reaction at contact points of uncovered and partially covered SEMSs make their endoscopic removal difficult. Although more studies are required, a feasibility trial in humans has demonstrated that fully covered SEMSs can be removed safely at endoscopy after successful resolution of underlying strictures (both benign and malignant), fistulae, or leaks.⁸¹ Another recent study showed that fully covered SEMSs are efficacious in resolving benign strictures in 56% and fistulae, leaks, or perforation in 38% of patients.⁸² Although migration occurred in 35% of patients, these stents could be successfully retrieved without complications.

As with SEMS placement in the esophagus, perforation and bleeding are the most serious complications of gastroduodenal stent placement, occurring in 0.7% to 5% of patients, respectively.^{42,44} Stent migration (5%) and restenosis (18%) are typically late complications, and the majority of these complications can be managed with insertion of an additional stent.⁴⁴ One unique complication for gastroduodenal stent placement is precipitation of cholangitis or biliary obstruction caused by compression of the papilla.^{2,38,44} Because the papilla cannot typically be accessed after duodenal SEMS placement, a biliary SEMS should be placed before a duodenal SEMS when biliary obstruction is present or impending.

Perforation is the most severe complication of colonic SEMS occurring in 3.8% to 10% of patients.^{49,60} Predeployment dilation has been associated with an increased risk of perforation and hence is discouraged.⁸³ Other potential factors contributing to perforation include puncture of the colonic wall during guide-wire passage, erosion of the colonic wall by free wires at the end of the stent, administration of bevacizumab-based chemotherapy regimens, and intraluminal lesions.^{60,84} Stent migration and obstruction are generally delayed complications reported in 10% to 11.8% and 7.3% to 10% of patients, respectively.^{49,60} Stent placement low in the rectum can lead to severe tenesmus.⁸⁵ One study of 44 patients that provided long-term follow-up reported a complication rate of 51%, which included stent migration in 22%, obstruction 17%, perforation 7%, and tenesmus 5%.⁸⁶ Colonic stent placement for luminal obstruction secondary to extrinsic lesions is associated with an increased rate of stent migrations and occurred in 13% of patients in 1 study.^{87,88}

FINANCIAL CONSIDERATIONS

The list prices of the available enteral stents are provided in Table 1. Several cost analyses have suggested that stent costs are offset by the relative reduction in the number of surgical procedures and hospital days compared with alternative therapies. In a cost-minimization analysis from the United Kingdom, endoscopic palliation of esophageal cancer with SEMS placement yielded a lower cost per day of survival compared with alternative modalities.⁸⁹ Similarly, gastroduodenal stent placement yields 30% lower hospital costs compared with surgical palliation, whereas colonic stenting for palliation or preoperative decompression is associated with a 10% to 20% cost reduction.^{46,65,90} In a decision analysis that compared colonic stenting and surgery for acute malignant large-bowel obstruction, the stenting strategy was less costly by \$30,000.⁹¹ Likewise, duodenal stenting was found to be \$3900 less costly than surgical bypass for the palliation of malignant gastroduodenal obstruction.⁹²

As of 2005, there are specific CPT codes that must be used when performing stent placement in the alimentary tract, and facilities must include a separate code for the stent itself (Table 2). Although Centers for Medicare and Medicaid Services do not provide additional payment for the device, facilities are required to report these codes to permit cost tracking for future rate determinations. These requirements change frequently, and each facility should check with its local payers. Dilation of the stricture before stent placement is included in the stent procedure code. Fluoroscopic supervision when done by the physician inserting the stent is separately reported by using CPT 76000.

TABLE 2. CPT codes used when performing stent placement in the alimentary tract

CPT	Procedure
43219	Esophagoscopy with insertion of plastic tube or stent
43256	Upper GI endoscopy with stent placement (includes predilation)
44370	Small-bowel endoscopy with stent placement (includes predilation)
44379	Small intestine endoscopy, enteroscopy beyond second portion of duodenum, not including ileum; with transendoscopic stent placement (includes predilation)
44383	Ileoscopy, through stoma; with transendoscopic stent placement (includes predilation)
44397	Colonoscopy through stoma with stent placement (includes predilation)
45327	Proctosigmoidoscopy, rigid; with transendoscopic stent placement (includes predilation)
45345	Flexible sigmoidoscopy with stent placement (includes predilation)
45387	Colonoscopy proximal to splenic flexure with stent placement (includes predilation)
76000	Fluoroscopy (separate procedure), up to 1 hour physician time
Device codes	
C-1874	Stent covered/coated, with delivery system
C-1876	Stent noncovered/noncoated, with delivery system
APC code	
0384	Used for all GI stenting procedures

AREAS FOR FUTURE RESEARCH

The role of fully covered SEMSs in the treatment of benign esophageal strictures, fistulae, and leaks requires further evaluation in prospective trials. Also, its role as a bridge to surgery in esophageal cancer patients with dysphagia undergoing preoperative neoadjuvant therapy requires further evaluation. Prospective, randomized trials with particular emphasis on quality of life and cost-effectiveness are required that compare gastroduodenal stenting and surgery for palliation of malignant gastric outlet obstruction. There is a need for more data assessing the technical feasibility and clinical outcomes of SEPS and fully covered SEMS placement for the management of benign colonic strictures. Further research by using newer biodegradable and drug-eluting stents is needed to define their role. Development of new devices to prevent migration of stents is desirable.

SUMMARY

Obstruction of the digestive tract is a frequent cause of morbidity in patients with GI malignancies. The role of palliative stenting in the management of these patients has expanded in recent years to include the esophagus, stomach, small bowel, and colon. Stent placement also serves as an adjunct to definitive surgical therapy for obstructing colonic lesions because endoscopic decompression facilitates formal bowel cleansing and subsequent single-stage elective surgery. Stenting has also expanded into the realm of benign esophageal and colonic diseases, with preliminary data demonstrating their use for benign strictures and anastomotic leaks. Endoscopic capabilities are likely to expand with the advent of innovative stenting devices and techniques.

DISCLOSURE

The following authors disclosed financial relationships relevant to this publication: Dr. Varadarajulu: consultant to Olympus and Boston Scientific; Dr. Tokar: consultant to Boston Scientific, consultant to, speaker for, and educational grant from Fujinon, Inc. The other authors disclosed no financial relationships relevant to this publication.

Abbreviations: ASGE, American Society for Gastrointestinal Endoscopy; QOL, quality of life; SEMS, self-expandable metal stent; SEPS, self-expandable plastic stent.

REFERENCES

- Baron TH, Harewood GC. Enteral self-expandable stents. *Gastrointest Endosc* 2003;58:421-33.
- Baron TH. Expandable metal stents for the treatment of cancerous obstruction of the gastrointestinal tract. *N Engl J Med* 2001;344:1681-7.
- Ramirez FC, Dennert B, Zierer ST, et al. Esophageal self-expanding metallic stents—indications, practice, techniques, and complications: results of a national survey. *Gastrointest Endosc* 1997;45:360-4.
- Knyrim K, Wagner H, Bethge N, et al. A controlled trial of an expansive metal stent for palliation of esophageal obstruction due to inoperable cancer. *N Engl J Med* 1993;329:1302-7.
- Davies N, Thomas HG, Eyre-Brook IA. Palliation of dysphagia from inoperable esophageal carcinoma using Atkinson tubes or self-expanding metal stents. *Ann R Coll Surg Engl* 1998;80:394-7.
- Depalma GD, Matteo E, Romano G, et al. Plastic prosthesis versus expandable metal stents for palliation of inoperable esophageal thoracic carcinoma: a controlled prospective study. *Gastrointest Endosc* 1996;43:478-82.
- Bethge N, Sommer A, Vakil N. Palliation of malignant esophageal obstruction due to intrinsic and extrinsic lesions with expandable metal stents. *Am J Gastroenterol* 1998;93:1829-32.
- Aoki T, Osaka Y, Takagi Y, et al. Comparative study of self-expandable metallic stent and bypass surgery for inoperable esophageal cancer. *Dis Esophagus* 2001;14:208-11.
- Homs MYV, Steyerber EW, Eijkenboom WMH, et al. Single-dose brachytherapy versus metal stent placement for the palliation of dysphagia from esophageal cancer: multicenter randomized trial. *Lancet* 2004;364:1497-504.

10. Adam A, Ellul J, Watkinson AF, et al. Palliation of inoperable esophageal carcinoma: a prospective randomized trial of laser therapy and stent placement. *Radiology* 1997;202:344-8.
11. Siersema PD, Hop WCJ, van Blankenstein M, et al. A comparison of 3 types of covered metal stents for the palliation of patients with dysphagia caused by esophagogastric carcinoma: a prospective, randomized study. *Gastrointest Endosc* 2001;54:145-53.
12. May A, Hahm E, Ell C. Self-expanding metal stents for palliation of malignant obstruction in the upper gastrointestinal tract: comparative assessment of three stent types implemented in 96 implantations. *J Clin Gastroenterol* 1996;22:261-6.
13. Dorta G, Binek J, Blum AL, et al. Comparison between esophageal Wall-stent and Ultraflex stents in the treatment of malignant stenosis of the esophagus and cardia. *Endoscopy* 1997;29:149-54.
14. Profili S, Meloni GB, Feo CF, et al. Self-expandable metal stents in the management of cervical oesophageal and/or hypopharyngeal strictures. *Clin Radiol* 2002;57:1028-33.
15. Bethge N, Sommer A, Vakili N. A prospective trial of self-expanding metal stents in the palliation of malignant esophageal strictures near the upper esophageal sphincter. *Gastrointest Endosc* 1997;45:300-3.
16. Vakili N, Morris AI, Marcon N, et al. A prospective, randomized, controlled trial of covered expandable metal stents in the palliation of malignant esophageal obstruction at the gastroesophageal junction. *Am J Gastroenterol* 2001;96:1791-6.
17. Dua KS, Kozarek R, Kim J, et al. Self-expanding metal esophageal stent with anti-reflux mechanism. *Gastrointest Endosc* 2001;53:603-13.
18. Laasch HU, Marriott A, Wilbraham L, et al. Effectiveness of open versus antireflux stents for palliation of distal esophageal carcinoma and prevention of symptomatic gastroesophageal reflux. *Radiology* 2002;225:359-65.
19. Homs MY, Wahab PJ, Kuipers EJ, et al. Esophageal stents with antireflux valve for tumors of the distal esophagus and gastric cardia: a randomized trial. *Gastrointest Endosc* 2004;60:695-702.
20. Shim CS, Jung IS, Cheon YK, et al. Management of malignant stricture of the esophagogastric junction with a newly designed self-expanding metal stent with an antireflux mechanism. *Endoscopy* 2005;37:335-9.
21. Power C, Byrne P, Lim K, et al. Superiority of anti-reflux stent with conventional stent in the palliative management of patients with cancer of the lower esophagus and esophago-gastric junction: results of a randomized clinical trial. *Dis Esophagus* 2007;20:466-70.
22. Rajman I. Endoscopic management of esophagorespiratory fistulas: expanding our options with expandable stents. *Am J Gastroenterol* 1998;93:496-9.
23. Kozarek RA, Raltz S, Marcon N, et al. Use of the 25 mm flanged esophageal Z stent for malignant dysphagia: a prospective multicenter trial. *Gastrointest Endosc* 1997;46:156-60.
24. Kozarek RA, Raltz S, Brugge WR, et al. Prospective multicenter trial of esophageal Z-stent placement for malignant dysphagia and tracheo-esophageal fistula. *Gastrointest Endosc* 1996;44:562-7.
25. Shin JH, Song HY, Ko GY, et al. Esophagorespiratory fistula: long-term results of palliative treatment with covered expandable metallic stents in 61 patients. *Radiology* 2004;232:252-9.
26. Van den Bongard HJ, Boot H, Baas P, et al. The role of parallel stent insertion in patients with esophagorespiratory fistulas. *Gastrointest Endosc* 2002;55:110-5.
27. Dormann AJ, Eisendrath P, Wiggingshaus B, et al. Palliation of esophageal carcinoma with a new self-expanding plastic stent. *Endoscopy* 2003;35:207-11.
28. Bethge N, Vakili N. A prospective trial of a new self-expanding plastic stent for malignant esophageal obstruction. *Am J Gastroenterol* 2001;96:1350-4.
29. Evrard S, Le Moine O, Lazaraki G, et al. Self-expanding plastic stents for benign esophageal lesions. *Gastrointest Endosc* 2004;60:894-900.
30. Repici A, Conio M, De Angelis C, et al. Temporary placement of an expandable polyester silicone-covered stent for treatment of refractory benign esophageal strictures. *Gastrointest Endosc* 2004;60:513-9.
31. Hunerbein M, Stroszczyński C, Kurt M, et al. Treatment of thoracic anastomotic leaks after esophagectomy with self-expanding plastic stents. *Ann Surg* 2004;240:801-7.
32. Bower M, Jones W, Vessels B, et al. Nutritional support with endoluminal stenting during neoadjuvant therapy for esophageal malignancy. *Ann Surg Oncol* 2009;61:3161-8.
33. Adler DG, Fang J, Wong R, et al. Placement of polyflex stents in patients with locally advanced esophageal cancer is safe and improves dysphagia during neoadjuvant therapy. *Gastrointest Endosc* 2009;70:614-9.
34. Siddiqui AA, Loren D, Dudnick R, et al. Expandable polyester silicone-coated stent for malignant esophageal strictures before neoadjuvant chemoradiation: a pilot study. *Dig Dis Sci* 2007;52:823-9.
35. Langer FB, Schoppmann SF, Prager G, et al. Temporary placement of self-expanding oesophageal stents as bridging for neo-adjuvant therapy. *Ann Surg Oncol* 2010;17:470-5.
36. Shin JH, Song HY, Kim JH, et al. Comparison of temporary and permanent stent placement with concurrent radiation therapy in patients with esophageal carcinoma. *J Vasc Interv Radiol* 2005;16:67-74.
37. Lindsay JO, Andreyev HJ, Vlavianos P, et al. Self-expanding metal stents for the palliation of malignant gastroduodenal obstruction in patients unsuitable for surgical bypass. *Aliment Pharmacol Ther* 2004;19:901-5.
38. Adler DG, Baron TH. Endoscopic palliation of malignant gastric outlet obstruction using self-expanding metal stents: experience in 36 patients. *Am J Gastroenterol* 2002;97:72-8.
39. Maetani I, Tada T, Shimura J, et al. Technical modifications and strategies for stenting gastric outlet strictures using esophageal endoprosthesis. *Endoscopy* 2002;34:402-6.
40. Yim HB, Jacobson BC, Saltzman JR, et al. Clinical outcome of the use of enteral stents for palliation of patients with malignant upper GI obstruction. *Gastrointest Endosc* 2001;53:329-2.
41. van Hooft JE, Uitdehaag MJ, Bruno MJ, et al. Efficacy and safety of the new WallFlex enteral stent in palliative treatment of malignant gastric outlet obstruction (DUOFLEX study): a prospective multicenter study. *Gastrointest Endosc* 2009;69:1059-66.
42. Piesman M, Kozarek RA, Brandabur JJ, et al. Improved oral intake after palliative duodenal stenting for malignant obstruction: a prospective multicenter clinical trial. *Am J Gastroenterol* 2009;104:2404-11.
43. Shaw JM, Bornman PC, Krige JEJ, et al. Self-expanding metal stents as an alternative to surgical bypass for malignant gastric outlet obstruction. *Br J Surg* 2010;97:872-6.
44. Dormann A, Meisner S, Verin N, et al. Self-expandable metal stents for gastroduodenal malignancies; systematic review of their clinical effectiveness. *Endoscopy* 2004;36:543-50.
45. Fiori E, Lamazza A, Volpino P, et al. Palliative management of malignant antro-pyloric strictures. Gastroenterostomy vs endoscopic stenting: a randomized prospective trial. *Anticancer Res* 2004;24:269-72.
46. Johnsson E, Thune A, Liedman B. Palliation of malignant gastroduodenal obstruction with open surgical bypass or endoscopic stenting: clinical outcome and health economic evaluation. *World J Surg* 2004;28:812-7.
47. Jeurnink SM, Steyerberg EW, Hof G, et al. Gastrojejunostomy versus stent placement in patients with malignant gastric outlet obstruction: a comparison in 95 patients. *J Surg Oncol* 2007;96:389-96.
48. Repici A, Reggion D, De Angelis C, et al. Covered metal stents for management of inoperable malignant colorectal strictures. *Gastrointest Endosc* 2000;52:735-40.
49. Sebastian S, Johnston S, Geoghegan T, et al. Pooled analysis of the efficacy and safety of self-expanding metal stenting in malignant colorectal obstruction. *Am J Gastroenterol* 2004;99:2051-7.
50. Lee KM, Shin SJ, Hwang JC, et al. Comparison of uncovered stent with covered stent for treatment of malignant colorectal obstruction. *Gastrointest Endosc* 2007;66:931-6.
51. Choo IW, Do YS, Suh SW, et al. Malignant colorectal obstruction: treatment with a flexible covered stent. *Radiology* 1998;200:415-21.
52. Repici A, Adler DG, Gibbs CM, et al. Stenting of the proximal colon in patients with large bowel obstruction: techniques and outcomes. *Gastrointest Endosc* 2007;66:940-4.

53. Dronamraju SS, Ramamurthy S, Kelly SB, et al. Role of self-expanding metallic stents in the management of malignant obstruction of the proximal colon. *Dis Colon Rectum* 2009;52:1657-61.
54. Khot UP, Wenk Lang A, Murali K, et al. Systematic review of the efficacy and safety of colorectal stents. *Br J Surg* 2002;89:1096-102.
55. Dauphine CE, Tan P, Beart RW, et al. Placement of self-expanding metal stents for acute malignant large-bowel obstruction: a collective review. *Ann Surg Oncol* 2002;9:574-9.
56. Mainar A, De Gregorio Ariza MA, Tejero E, et al. Acute colonic obstruction: treatment with self-expandable metallic stents before scheduled surgery: results of a multicenter study. *Radiology* 1999;210:65-9.
57. Martinez-Santos C, Lobato RF, Fradejas JM, et al. Self-expandable stent before elective surgery vs emergency surgery for the treatment of malignant colorectal obstructions: comparison of primary anastomosis and morbidity rates. *Dis Colon Rectum* 2002;45:401-6.
58. Repici A, Fregonese D, Costamagna G, et al. Ultraflex precision colonic stent placement for palliation of malignant colonic obstruction: a prospective multicenter study. *Gastrointest Endosc* 2007;66:920-7.
59. Repici A, Caro GD, Luigiano C, et al. Wallflex colonic stent placement for management of malignant colonic obstruction: a prospective study at two centers. *Gastrointest Endosc* 2008;67:77-84.
60. Small AJ, Coelho-Prabhu N, Baron TH. Endoscopic placement of self-expandable metal stents for malignant colonic obstruction: long-term outcomes and complication factors. *Gastrointest Endosc* 2010;71:560-72.
61. Fregonese D, Naspetti R, Ferrer R, et al. Ultraflex precision colonic stent placement as a bridge to surgery in patients with malignant colonic obstruction. *Gastrointest Endosc* 2008;67:68-73.
62. Brehant O, Fuks D, Bartoli E, et al. Elective (planned) colectomy in patients with colorectal obstruction after placement of a self-expanding metallic stent as a bridge to surgery: the results of a prospective study. *Colorectal Dis* 2009;11:178-83.
63. Tilney HS, Lovegrove RE, Purkayastha S, et al. Comparison of colonic stenting and open surgery for malignant large bowel obstruction. *Surg Endosc* 2007;21:225-33.
64. Vemulapalli R, Lara LF, Sreenarasimhaiah J, et al. A comparison of palliative stenting or emergent surgery for incurable colon cancer. *Dig Dis Sci* 2010;55:1732-7.
65. Targownik LE, Spiegel BM, Sack J, et al. Colonic stent vs emergency surgery for management of acute left-sided malignant colonic obstruction: a decision analysis. *Gastrointest Endosc* 2004;60:865-74.
66. Cheung HYS, Chung CC, Tsang WWC, et al. Endolaparoscopic approach vs conventional open surgery in the treatment of obstructing left-sided colon cancer. *Arch Surg* 2009;144:1127-32.
67. Nagula S, Ishill N, Nash C, et al. Quality of life and symptom control after stent placement or surgical palliation of malignant colorectal obstruction. *J Am Coll Surg* 2010;210:45-53.
68. García-Cano J. Dilatation of benign strictures in the esophagus and colon with the polyflex stent: a case series study. *Dig Dis Sci* 2008;53:341-6.
69. Keranen I, Lepisto A, Udd M, et al. Outcomes of patients after endoluminal stent placement for benign colorectal obstruction. *Scand J Gastroenterol* 2010;45:725-31.
70. van Boeckel PG, Repici A, Vleggaar FP, et al. A new metal stent with a controlled-release system for palliation of malignant dysphagia: a prospective, multicenter study. *Gastrointest Endosc* 2010;71:455-60.
71. Dasgupta A, Jain P, Sandur S, et al. Airway complications of esophageal self-expanding metallic stent. *Gastrointest Endosc* 1998;47:532-5.
72. Chan KP, Eng P, Hsu AA, et al. Rigid bronchoscopy and stenting for esophageal cancer causing airway obstruction. *Chest* 2002;122:1069-72.
73. Baron TH. A practical guide for choosing an expandable metal stent for GI malignancies: is a stent by any other name still a stent? *Gastrointest Endosc* 2001;54:269-72.
74. Kozarek RA, Ball TJ, Brandabur JJ, et al. Expandable versus conventional esophageal prostheses: easier insertion may not preclude subsequent stent-related problems. *Gastrointest Endosc* 1996;43:204-8.
75. Bartelsman JFW, Bruno MJ, Jensema AJ, et al. Palliation of patients with esophagogastric neoplasms by insertion of a covered expandable modified Gianturco-Z endoprosthesis: experiences in 153 patients. *Gastrointest Endosc* 2000;51:134-8.
76. Cennamo V, Fuccio L, Mutri V, et al. Does stent placement for advanced colon cancer increase the risk of perforation during bevacizumab-based therapy? *Clin Gastroenterol Hepatol* 2009;7:1174-6.
77. Kinsman KJ, DeGregorio BT, Katon RM, et al. Prior radiation and chemotherapy increase the risk of life-threatening complications after the insertion of metallic stents for esophagogastric malignancy. *Gastrointest Endosc* 1996;43:196-203.
78. Wada S, Noguchi T, Takeno S, et al. Is a metallic stent useful for non resectable esophageal cancer? *Ann Thorac Cardiovasc Surg* 2004;10:224-8.
79. Homs MY, Hansen BE, van Blankenstein M, et al. Prior radiation and/or chemotherapy has no effect on the outcome of metal stent placement for esophagogastric carcinoma. *Eur J Gastroenterol Hepatol* 2004;16:163-70.
80. Kim JH, Too BM, Lee KJ, et al. Self-expanding coil stent with a long delivery system for palliation of unresectable malignant gastric outlet obstruction: a prospective study. *Endoscopy* 2001;33:838-42.
81. Eloubeidi MA, Lopes TL. Novel removable internally fully covered self-expanding metal esophageal stent: feasibility, technique of removal, and tissue response in humans. *Am J Gastroenterol* 2009;104:1374-81.
82. Bakken JC, Wong Kee Song LM, de Groen P, et al. Use of a fully covered self-expandable metal stent for the treatment of benign esophageal strictures. *Gastrointest Endosc* 2010;72:712-20.
83. Baron TH, Dean PA, Yates MR, et al. Expandable metal stents for the treatment of colonic obstruction: techniques and outcomes. *Gastrointest Endosc* 1998;47:277-85.
84. Camunez F, Echenagusia A, Simo G, et al. Malignant colorectal obstruction treated by means of self-expanding metallic stents: effectiveness before surgery and in palliation. *Radiology* 2000;216:492-7.
85. Turegano-Fuentes F, Echenagusia-Belda A, Simo-Muerza G, et al. Transanal self-expanding metal stents as an alternative to palliative colostomy in selected patients with malignant obstruction of the left colon. *Br J Surg* 1998;85:232-5.
86. Fernandez-Esparrach G, Bordas JM, Giraldez MD, et al. Severe complications limit long-term clinical success of self-expanding metal stents in patients with obstructive colorectal cancer. *Am J Gastroenterol* 2010;105:1087-93.
87. Miyayama, Matsui O, Kifune K, et al. Malignant colonic obstruction due to extrinsic tumor: palliative treatment with a self-expanding nitinol stent. *AJR Am J Roentgenol* 2000;175:1631-7.
88. Shin SJ, Kim KI, Kim BC, et al. Clinical application of self-expandable metallic stent for treatment of colorectal obstruction caused by extrinsic invasive tumors. *Dis Colon Rectum* 2008;51:578-83.
89. Nicholson DA, Haycox A, Kay CL, et al. The cost effectiveness of metal esophageal stenting in malignant disease compared with conventional therapy. *Clin Radiol* 1999;54:212-5.
90. Binkert CA, Ledermann H, Jost R, et al. Acute colonic obstruction: clinical aspects and cost-effectiveness of preoperative and palliative treatment with self-expanding metallic stents: a preliminary report. *Radiology* 1998;206:199-204.
91. Siddiqui A, Khandelwal N, Anthony T, et al. Colonic stent versus surgery for the management of acute malignant colonic obstruction: a decision analysis. *Aliment Pharmacol Ther* 2007;15:1379-86.
92. Siddiqui A, Spechler SJ, Huerta S. Surgical bypass versus endoscopic stenting for malignant gastroduodenal obstruction: a decision analysis. *Dig Dis Sci* 2007;52:276-81.

Prepared by:
 ASGE TECHNOLOGY COMMITTEE
 Shyam Varadarajulu, MD
 Subhas Banerjee, MD

Bradley Barth, MD
David Desilets, MD
Vivek Kaul, MD
Sripathi Kethu, MD
Marcos Pedrosa, MD
Patrick Pfau, MD
Jeffrey Tokar, MD

Amy Wang, MD
Louis-Michel Wong Kee Song, MD
Sarah Rodriguez, MD, Chair

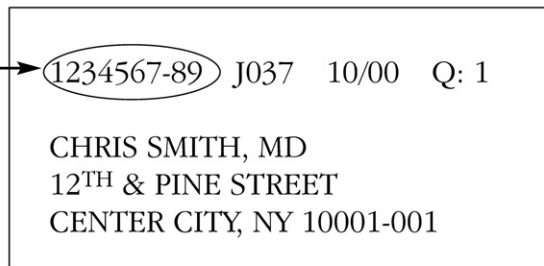
This document is a product of the ASGE Technology Assessment Committee. This document was reviewed and approved by the Governing Board of the ASGE.

Access to ***Gastrointestinal Endoscopy Online*** is reserved for all subscribers!

Full-text access to ***Gastrointestinal Endoscopy Online*** is available for all subscribers. ASGE MEMBER SUBSCRIBERS: To activate your individual online subscription, please visit <http://www.asge.org> and follow the instructions. NON-MEMBER SUBSCRIBERS: To activate your individual online subscription, please visit <http://www.giejournal.org> and follow the prompts to activate your *online access*. To activate your account, you will need your subscriber account/membership number, which you can find on your mailing label (*note*: the number of digits in your subscriber account number varies from 6 to 10 digits). See the example below in which the subscriber account number has been circled:

Sample mailing label

This is your Nonmember
subscriber account number



Personal subscriptions to ***Gastrointestinal Endoscopy Online*** are for individual use only and may not be transferred. Use of ***Gastrointestinal Endoscopy Online*** is subject to agreement to the terms and conditions as indicated online.